

EP-067

재발성 MRSA 양성 두피 결손에서
두개골 재건 없이 노출된 경막을 국소
회전 피판으로 덮은 증례 보고

(Local Rotation Flap Coverage Over Exposed Dura
Without Calvarial Reconstruction in a Recurrent
MRSA-Positive Scalp Defect: A Case Report)



순천향대학교 구미병원
김은찬, 김세영*

Background: Reconstruction of scalp defects with exposed dura after multiple prior operations is challenging, particularly in patients with diabetes and a history of MRSA infection. Coverage without calvarial reconstruction is generally considered high risk for infection and flap failure. This report describes successful reconstruction of a temporoparietal scalp defect with exposed dura using a local rotation flap without calvarial reconstruction in a patient with multiple prior infections.

Methods: A 42-year-old man with Moyamoya disease developed a temporoparietal 7x5 cm scalp defect with calvarial bone loss and dural exposure following STA-MCA bypass and prior rotational flap surgery (Fig 1). Preoperative images revealed bony defect with soft tissue changes (Fig 2,3). After radical debridement of nonviable tissue and irrigation, a local rotation flap was designed in the parieto-occipital scalp. A 10 × 8 cm curvilinear flap was elevated as a full-thickness scalp flap, including skin, subcutaneous tissue, and galea, in the subgaleal plane. The flap was rotated anteriorly and temporally to cover the exposed dura directly without bony reconstruction or synthetic material.

Results: Despite previous MRSA-positive wound cultures and elevated inflammatory markers, the flap survived completely without necrosis, dehiscence, or cerebrospinal fluid leakage. Serial laboratory monitoring showed no progression of infection. The wound remained stable with durable soft tissue coverage over the dura after 1 month follow-up (Fig 4).

Conclusions: A large posteriorly based local rotation flap can provide reliable coverage directly over exposed dura without calvarial reconstruction, especially in patients with prior MRSA infection, when meticulous debridement and infection control are ensured.

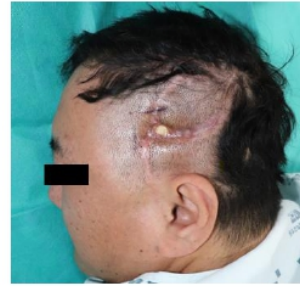

Figure 1. Preoperative clinical view. Preoperative lateral view of the right temporoparietal scalp demonstrating postoperative skin and soft tissue defect with wound breakdown following neurosurgical intervention.

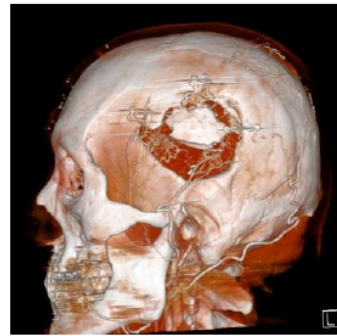


Figure 2. Preoperative imaging findings. Three-dimensional reconstructed computed tomography demonstrating the right 7 × 5 cm temporoparietal craniotomy defect with fixation hardware in situ.

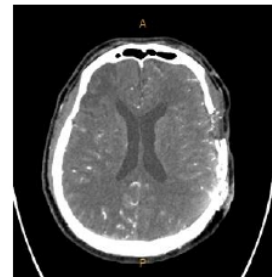


Figure 3. Preoperative axial CT image. Axial computed tomography scan showing the temporoparietal cranial defect and surrounding postoperative changes.

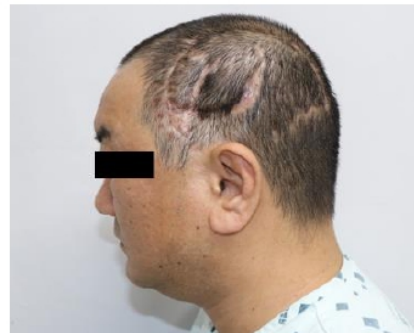

Figure 4. Postoperative clinical photo. Postoperative lateral view showing stable soft-tissue coverage of the right temporoparietal scalp following reconstruction with a local rotation flap after 1 month follow-up without any complications