

EP-070

이마에 발생한 고를린 증후군의 드문 증례 보고



한림대학교성심병원

김준일, 김재현,
정찬민*

Purpose: Gorlin syndrome, also known as Nevoid basal cell carcinoma syndrome (NBCCS), is a genetic disorder associated with basal cell carcinomas (BCCs) and skeletal anomalies. Typically patients show up with early-onset or multiple BCCs. This paper presents a patient with NBCCS on forehead with a rib abnormality and palmar pits

Methods: A 28-year-old female presented at our clinic with a BCC on forehead which was treated with wide excision (Fig. 1). The lesion was diagnosed by biopsy (Fig. 2). Subsequently, a second BCC emerged in a distinct region on the patient's forehead within a year (Fig. 3). The patient had palmar pits and further radiologic examination revealed a rib anomaly, specifically the absence of the 12th rib (Fig. 4). The correlation between these findings prompted a diagnosis of Gorlin syndrome. A second wide excision was performed to manage the recurrent BCC.

Results: The patient was discharged from the hospital three days post-surgery. The wound was stable, and a follow-up after three months with consultation to oncology confirmed the patient's complete recovery without any complications.

Conclusion: NBCCS, or Gorlin-Goltz syndrome, is a systemic condition along with multiple or early onset BCCs. While noticing BCC through biopsy may be straightforward, it is essential to make a multidisciplinary approach to a patient with possible NBCCS. The presence of recurrent BCCs, coupled with palmar pits and the absence of the 12th rib emphasizes that diagnosing should not be limited to cutaneous lesions but should encompass various systemic conditions.

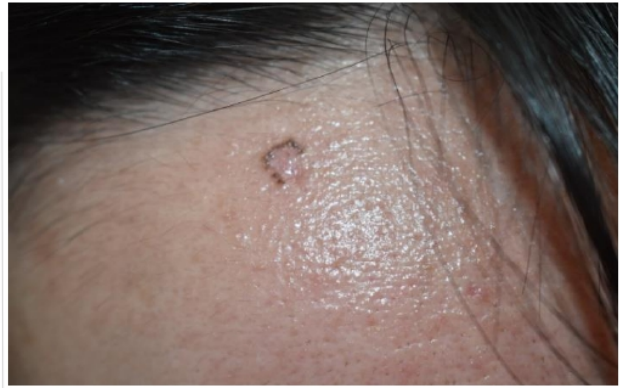

Fig 1. Preoperative gross photography of BCC (1st BCC: upper forehead)

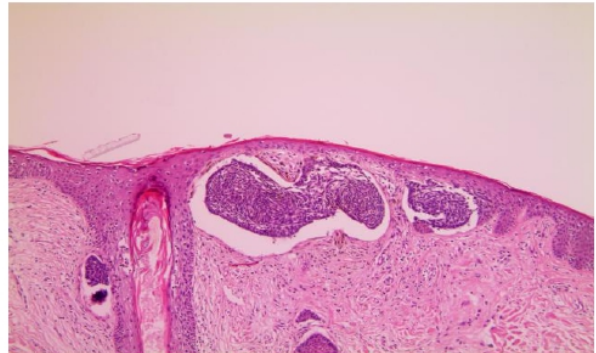


Fig 2. Basaloid cells with palisading seen in H&E staining (x100)

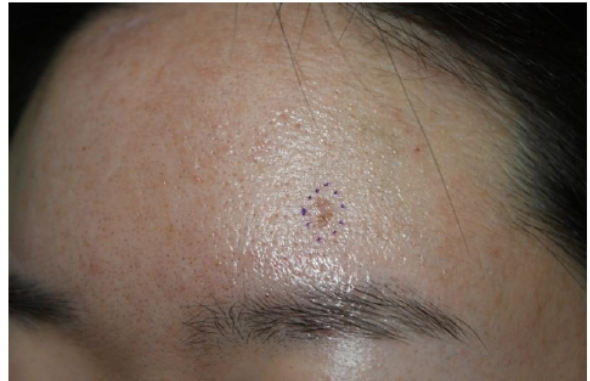

Fig 3. Preoperative gross photography of BCC (2nd BCC: left forehead)

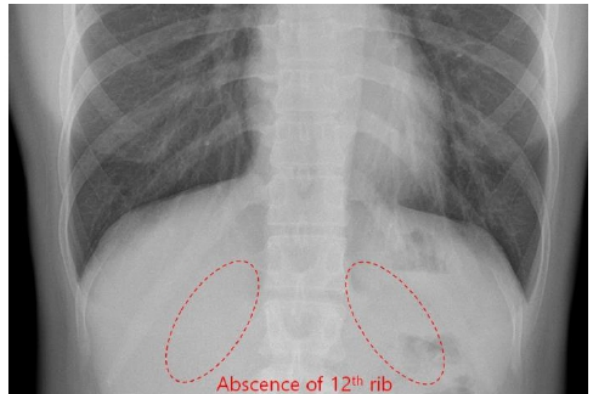


Fig 4. Radiologic findings: absence of the 12th rib