

EP-209

건 및 골 노출을 동반한 만성 난치성
창상에 대한 유리피판 재건술

(Free Flap Reconstruction for Longstanding
Non-Healing Wounds with Exposed Tendon
and Bone)



인하대학교
기세휘*, 정도혁

Purpose: Wound healing may be delayed despite conservative care or negative pressure wound therapy (NPWT). For longstanding wounds with exposed tendon and bone, free flap reconstruction can provide a definitive option. This study evaluated outcomes and complications of free flap reconstruction.

Methods: A retrospective review from 2012 to 2023 included 15 patients who underwent 16 free flap reconstructions for chronic tendon and bone exposure. Data on demographics, wound causes, flap success, healing time, and complications were analyzed.

Results: Of 16 reconstructions, 8 used anterolateral thigh (ALT) free flaps, 5 lateral arm (LAFF), 2 latissimus dorsi musculocutaneous (LDMC), and 1 fibular osteocutaneous flap. The mean flap size was 12 × 7 cm², with an average wound exposure of 9 months. Causes included vehicle accidents (n=5), thermal burns (n=4), falls (n=3), postoperative complications (n=2), chemical burns (n=1), and industrial accidents (n=1). Nine complications occurred: partial flap necrosis (n=3), tendinitis (n=2), osteomyelitis (n=2), and wound dehiscence (n=1). All were managed successfully with local flaps, grafting, NPWT, or conservative treatment.

Conclusion: Chronic tendon and bone exposure is often associated with biofilm and subclinical infection, contributing to delayed healing. Free flap reconstruction provided stable coverage without major complications, though minor problems such as infection or partial flap loss were relatively frequent.

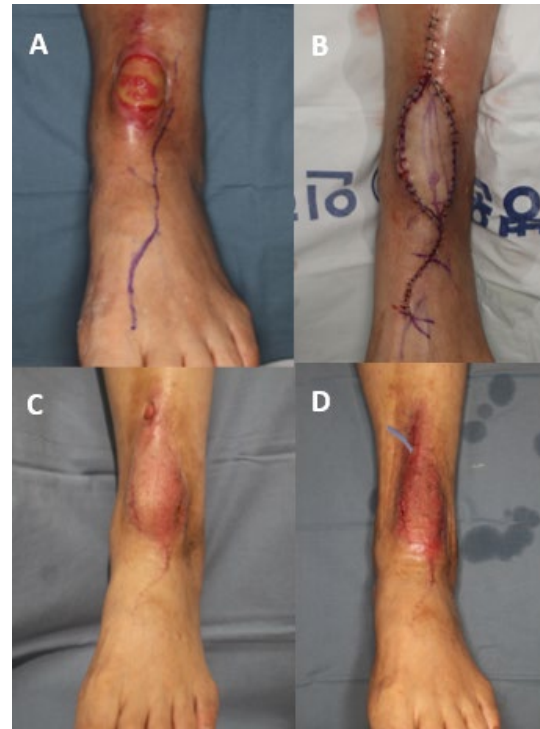

Fig. 1. (A) Tendon exposure (B) Coverage with lateral arm free flap (C) Postsoperative photograph, fistula formation (D) Closure with secondary closure

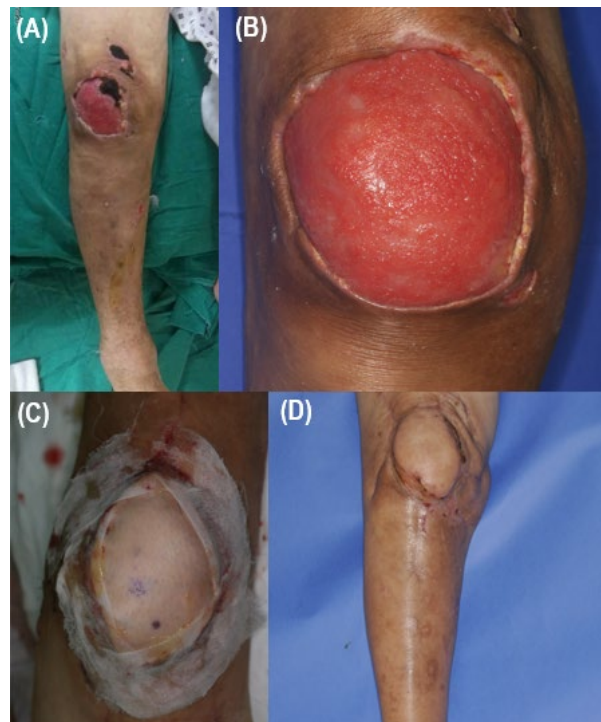


Fig. 2. (A) Patella exposure (B) Capsulated wound bed with biofilm formation (C) Postsoperative photograph, Coverage with ALT free flap (D) Postoperative 6 months