

EP-224

근육 내 거대 고분화 지방육종 절제 후 사지 보존에 성공한 증례

(Successful Limb Salvage After Resection of a Giant Intramuscular Well-Differentiated Liposarcoma)



순천향대학교 부속 서울병원

최현범, 김철한\*

**Purpose:** Well-differentiated liposarcoma (WDLPS) occurring within intramuscular compartments may extend to adjacent osseous structures, posing challenges in achieving oncologic clearance while preserving limb function. We report a case of intramuscular WDLPS of the medial thigh adherent to the femur, successfully managed with limb-salvage resection.

**Methods:** A 63-year-old woman presented with a progressively enlarging mass in the right medial thigh for 5 years. Magnetic resonance imaging demonstrated a lipomatous lesion within the vastus medialis muscle (Fig. 1). Intraoperatively, an intramuscular mass measuring approximately 20 cm in greatest dimension was identified within the vastus medialis, with the base of the mass adherent to the femur (Fig. 2). Marginal excision of the mass was achieved, with preservation of the femur except for partial excision of the periosteum (Fig. 3).

**Results:** Histopathological examination revealed a well-differentiated liposarcoma with negative surgical margins. Follow-up imaging has demonstrated no evidence of local recurrence, and postoperatively, limb function was fully preserved without any deficits.

**Conclusion:** Wide excision of giant intramuscular WDLPS provides maximal oncologic safety. Nevertheless, careful marginal excision, with selective resection of the periosteum when the tumor is adherent to the femoral surface, can achieve complete oncologic clearance while preserving limb function.

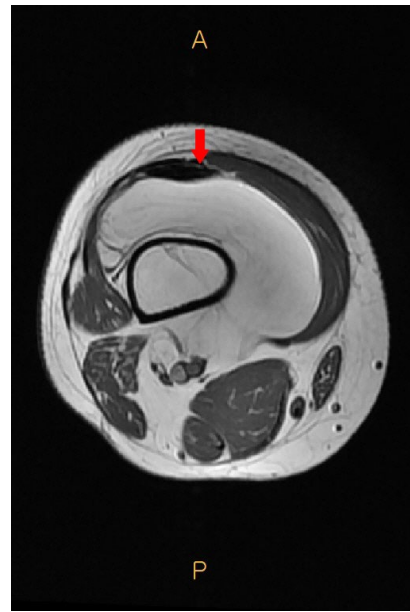


Fig. 1. Preoperative contrast-enhanced magnetic resonance imaging (axial view) demonstrating a large lipomatous mass within the medial thigh surrounding the femur.

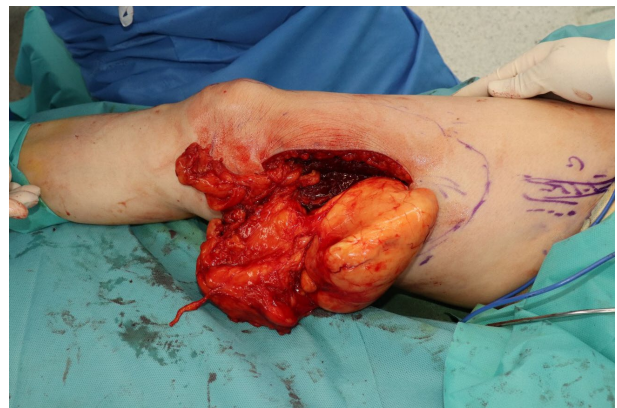


Fig. 2. Intraoperative photograph showing the giant intramuscular mass in the right medial thigh, measuring approximately 20 cm in greatest dimension.

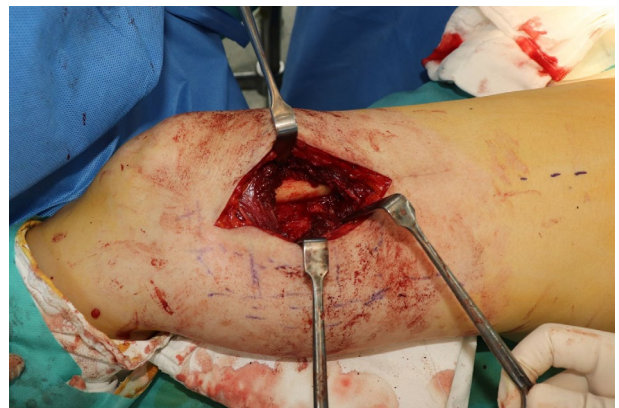

Fig. 3. Intraoperative photograph obtained after complete tumor resection, showing exposure of the distal femur following removal of the adherent mass.