

EP-246

반려 단안코브라에 의한 독상 후 발생한 전완부 중증 연부조직 괴사를 변연절제술과 부분층 피부이식으로 치료한 증례



한림대학교성심병원
심승용*, 김재현, 정찬민

Purpose: Monocled cobra envenomation can cause severe cytotoxic injury leading to progressive soft tissue necrosis. With the increasing ownership of exotic reptiles, snakebite injuries from pet venomous snakes are emerging as a clinical concern. This report presents a case of severe forearm necrosis caused by a pet monocled cobra and its surgical management.

Methods: A 17-year-old male presented with a $1.7 \times 0.5 \times 3$ cm necrotic wound on the left forearm following monocled cobra envenomation, for which antivenom had been administered. A central eschar with surrounding soft tissue necrosis was noted (Figure 1). MRI demonstrated intramuscular involvement with a localized necrotic cavity (Figure 2). Extensive debridement under general anesthesia revealed subcutaneous fat necrosis with partial muscle involvement extending beyond clinically visible margins (Figure 3). After removal of all nonviable tissue, incision and drainage were performed, followed by split-thickness skin grafting (STSG) for definitive coverage.

Results: Complete removal of necrotic tissue was achieved, and the defect was reconstructed with STSG. The graft showed satisfactory take without recurrent infection. During follow-up through July 11, 2025, the wound healed progressively with preserved forearm contour and no major complications (Figure 4)

Conclusion: Monocled cobra envenomation may cause deep tissue and muscle necrosis requiring aggressive surgical management. Early debridement and appropriate reconstruction can result in favorable outcomes, highlighting the need for vigilance in injuries related to exotic pet ownership.

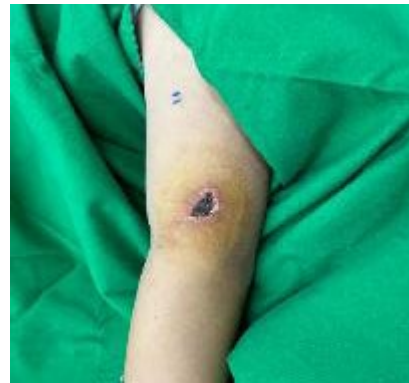

Fig 1. Preoperative gross photography

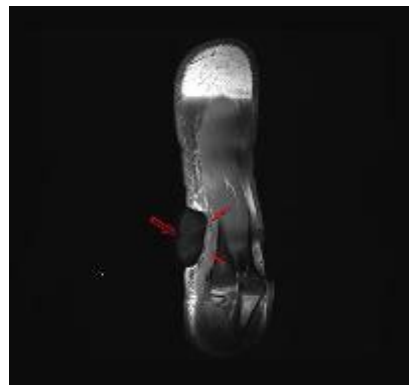


Fig 2. Preoperative Magnetic Resonance Imaging (MRI)

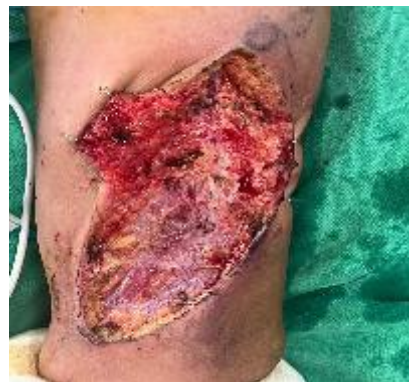

Fig 3. Intraoperative gross photography

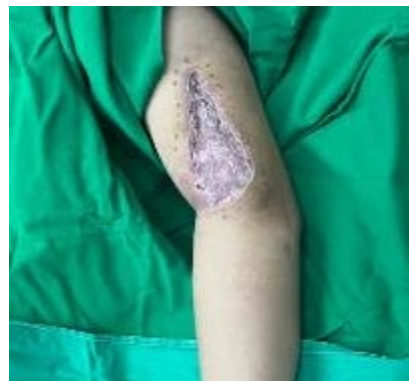

Fig 4. Post operative gross photography